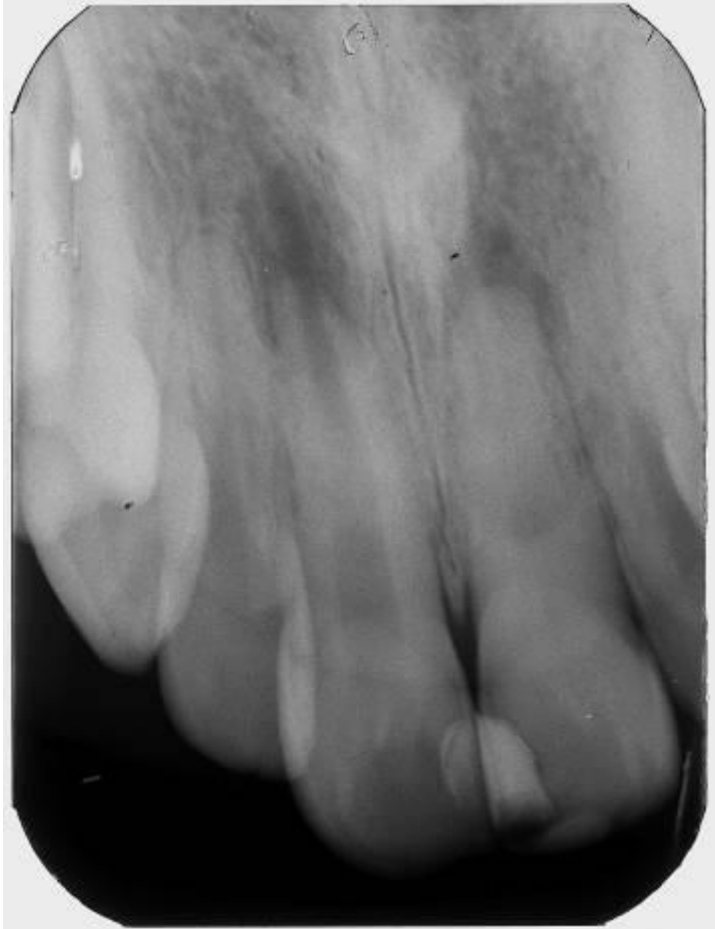

# **Two Upper Central Incisors Presenting Periapical Radiolucencies**

Patient: DH 25 y/o Female

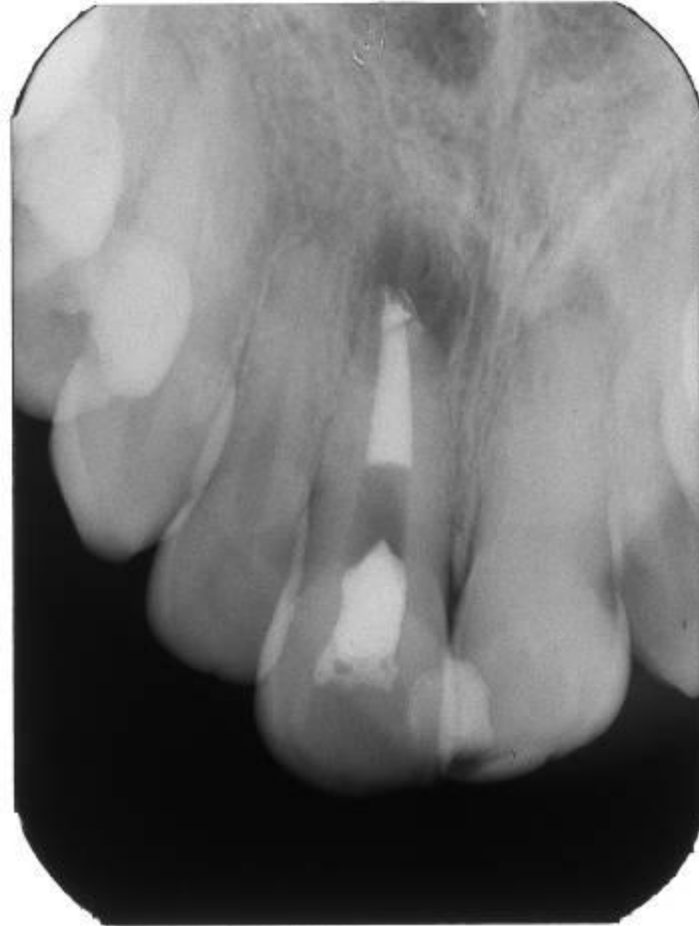Operator: Dr. Osnat Keisar Endodontic Specialist

# Diagnostic X-ray



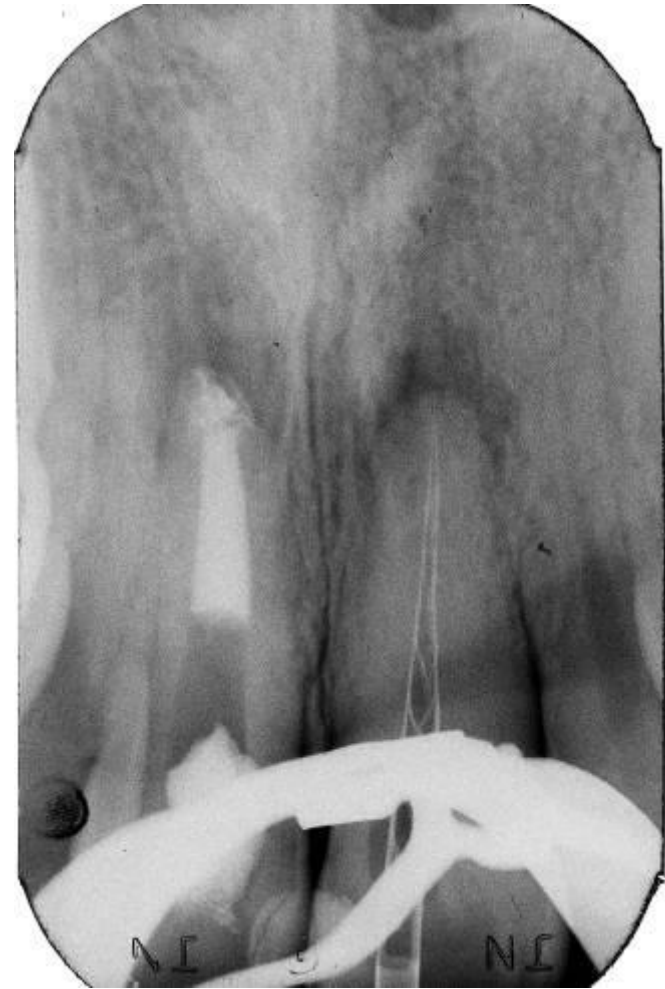
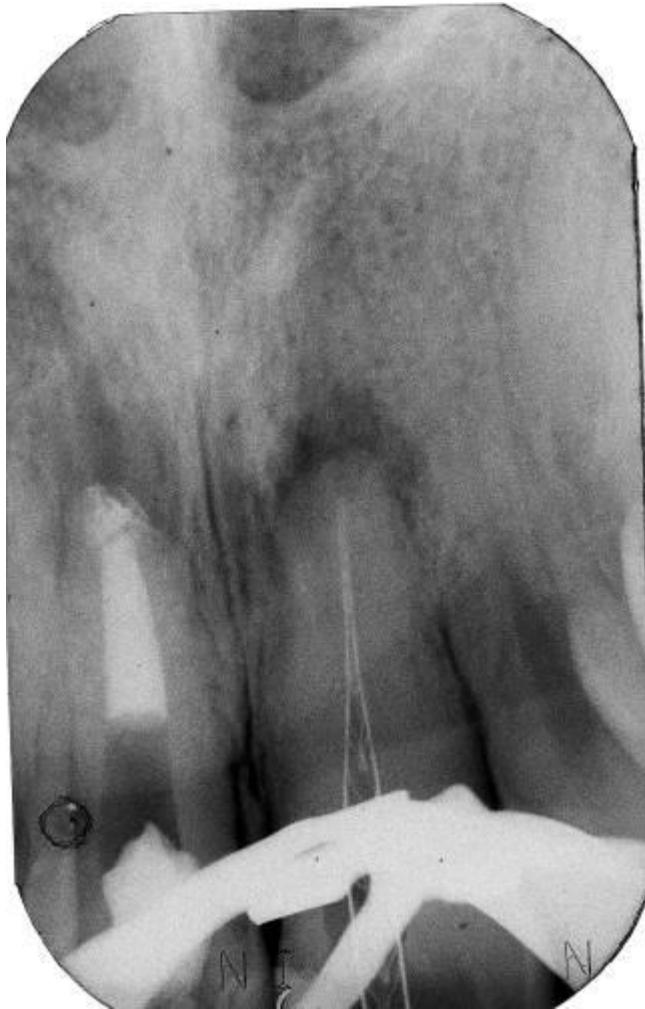- DH, 25 y/o Female, referred by her orthodontist
- Non-vital central incisors presenting large PA lesions.
- Reported history of trauma to the teeth during childhood.
- Mesial composite restoration with secondary carious lesions.

# Right Upper Central Incisor (11)



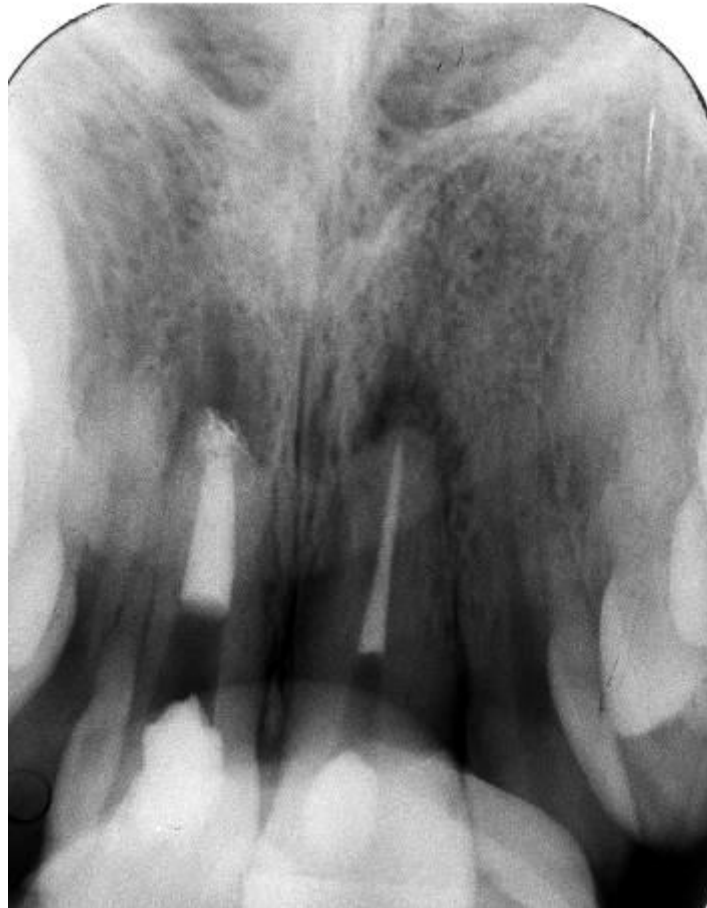Tooth obturated using lateral condensation technique following SAF treatment (3 minutes of NaOCl irrigation + 1 min EDTA)

# Left Upper Central Incisor (21)



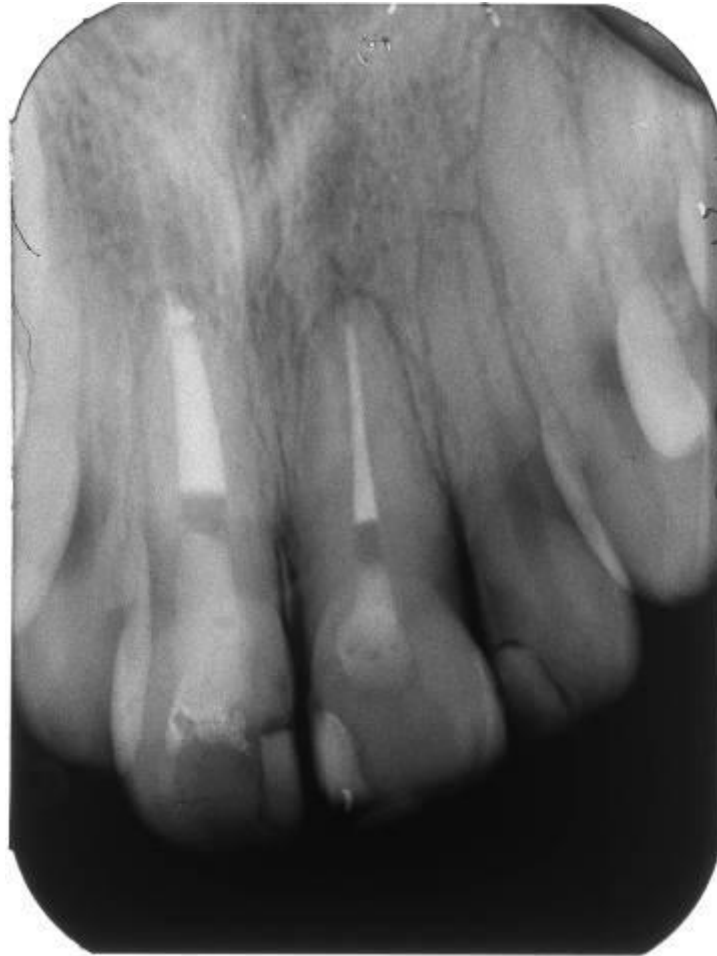SAF inserted to working length  
(Left - start of treatment; Right - end of treatment)

# Left Upper Central Incisor (21)



Tooth obturated using lateral condensation technique following SAF treatment (3 minutes of NaOCl irrigation + 1 min EDTA)

# One Year Follow-up



Asymptomatic tooth,  
Complete healing of periapical lesions